

## Treatment of the foreign body induced occlusive ileus in dogs

**Darko Capak<sup>1\*</sup>, Antun Brkić<sup>1</sup>, Ivica Harapin<sup>2</sup>, Dražen Matičić<sup>1</sup>,  
and Berislav Radišić<sup>1</sup>**

<sup>1</sup>*Clinic for Surgery, Orthopaedics and Ophthalmology, Faculty of Veterinary Medicine  
University of Zagreb, Zagreb, Croatia*

<sup>2</sup>*Clinic for Internal Diseases, Faculty of Veterinary Medicine  
University of Zagreb, Zagreb, Croatia*

---

**CAPAK, D., A. BRKIĆ, I. HARAPIN, D. MATIČIĆ, B. RADIŠIĆ: Treatment of the  
foreign body induced occlusive ileus in dogs. Vet. arhiv 71, 345-359, 2001.**

### ABSTRACT

The records of 123 cases, treated at the Clinic for Surgery, Orthopaedics and Ophthalmology of the Faculty of Veterinary Medicine, University of Zagreb, from January 1981 to December 1998 were analysed. Analysis included the incidence of ileus caused by foreign bodies, and the distribution of patients by sex, age, breed, duration of illness, site of obstruction, types of foreign bodies and the interrelation between these parameters. Results of our research show that the number of patients with foreign body induced ileus is increasing. Males ingested foreign bodies more often than females. Foreign body induced ileus was more frequently found in animals under the age of 2 years. Foreign bodies were mostly ingested by mongrels, but also by popular dog breeds such as Dobermann, Poodle, German Shepherd and Cocker Spaniel. Most of these ileus cases were treated in June and October and the predominant clinically signs included anorexia, dehydration, abdominal tenderness and absence of defecation. The most common site of small intestine obstruction by foreign bodies was the jejunum, the most effective treatment being enterotomy. Dogs mostly ingested stones, and plastic and rubber objects. Treatment was more successful in dogs below 2 years of age. Patients that died post-surgically died mostly during the first day after surgery.

**Key words:** foreign bodies, ileus, digestive system, dog

---

\* Contact address:

Prof. Dr. sc. Darko Capak, Clinic for Surgery, Orthopaedics and Ophthalmology, Faculty of Veterinary Medicine, University of Zagreb, Heinzelova 55, 10000 Zagreb, Croatia, Phone: +385 1 2390-383; Fax: +385 1 2390-390; Email: dcapak@vef.hr

## Introduction

Occlusive ileus is a frequent disease in dogs and therefore continues to be in the focus of clinical attention. The first clinical data about foreign body induced ileus in literature appeared at the beginning of the 20<sup>th</sup> century (ÜBERREITER, 1932) and continuing up to contemporary times (CHRISTOPH, 1953; CLARK, 1968; KOIKE et al., 1981; BÖHMER et al., 1990). Data on occurrence, diagnostics and treatment are also available from the 1930s up to the present day: LEHR (1929), ÜBERREITER (1932), CHRISTOPH (1953), POBISCH (1960), CLARK (1968), KOIKE et al. (1981), LANTZ (1981), FORENBACHER (1983), GRYGAR and CHLEBOVSKY (1987), DIETZ et al. (1988), LAWSON et al. (1989), WILLIAMS (1989), BÖHMER et al. (1990), CAPAK and BUTKOVIĆ (1991), HUNT et al. (1991), SLATTER (1993), CUNNINGHAM (1997), KYLES et al. (1998), MANCZUR et al. (1998).

Since intestinal obstruction in dogs caused by ingestion of foreign bodies shows a rising trend (CAPAK and BUTKOVIĆ, 1991), the purpose of this paper is to investigate its occurrence and frequency in Croatia over the last 18 years.

## Materials and methods

*Animals.* The research was based on the records of the dogs treated at the Clinic for Surgery, Orthopaedics and Ophthalmology of the Faculty of Veterinary Medicine in Zagreb. The data refer to the period from 1 January 1981 to 31 December 1998, when 19634 dogs were treated at the Clinic. From the total number of dogs we selected 123 animals treated for mechanically induced ileus caused by ingestion of a foreign body. These animals included 83 males and 40 females, divided into two groups by age: from 7 weeks to 2 years (n=51) and from 2 to 12 years (n=72). Of these 123 dogs, 20 were mongrels while 103 originated from 31 different breeds.

During their stay at the Clinic the dogs were kept in metal cages with a wooden floor. Microclimate conditions were optimal for the animals of that particular type and age. Feeding was adapted to the requirements of their illness. The first day after surgery, animals received food and liquids intravenously (glucosaline, Ringer lactate, saline). On the first and second day they were given tea *per os*, and on the third day they were given liquid

food (meat soup) *per os*. Subsequently, meat - with other food on the side - was introduced in daily increasing quantities.

*Clinical examination.* After arrival at the Clinic, initial information about the development of the disease was provided by the owner. Data taken at the first examination included the data from the matriculation form (breed, sex, age and colour) and *status presens* determining the general condition (habitus, constitution, posture, fattening and overall behaviour). Particular attention was paid to examination of the digestive tract.

*X-Ray examination.* In most animals, X-ray examination was applied as an auxiliary method by means of a 200 kV Siemens-Müller U6F-1958 unit, at 100-cm distance between the anode and the film, in two recumbencies: dorso-lateral (D-V) and latero-lateral (L-L). Subject to the size of the animal, the features of the X-ray examination in D-V and L-L were, 70-85 kV and 25-30 mAs i. e. 65-80 kV and 20-30 mAs, respectively. Saphir Universal foils and ORWO HS-90 film sizes 24x30 and 30x40 cm were used. Native shots were made for the foreign body diagnosis, such as stone, metal, glass and bone, while contrast means were used for other foreign bodies.

*Treatment.* Of the 123 animals, one dog was treated conservatively and 122 were treated by a combination of conservative treatment and surgery. For the conservative treatment, intravenous (i/v) and subcutaneous (s/c) infusions were used (glucosaline 5%, saline, Ringer lactate), drugs for improvement of general resistance and faster recovery (vitamin AD<sub>3</sub>E, vitamin C, and B-complex) and antibiotics for prevention of infections (procaine benzilpenicillin and streptomycin, sulfamethoxypyridazine, benzathine benzilpenicillin, gentamycin, lincomycine, lincospectin).

Surgical treatment, with previous sedation and narcosis (2% xilocaine and 2%-procainamide, Combelen, Heptanon, ketamine, atropine) included enterotomy, gastrotomy and intestine resection.

## Results

*Animals.* Of the total number of 19634 dogs treated at the Clinic for Surgery, Orthopaedics and Ophthalmology of the Faculty of Veterinary

Medicine in the period between 1 January 1981 and 31 December 1998, 123 dogs, (0.62%) were taken into account (Table 1).

Results show that the number of dogs that ingested a foreign body ranged from one case in 1982 to 13 cases in 1995 and 1996. Of them 67% were males and 33% females. Average age was 3.18 years.

Table 1. Dogs presenting foreign body induced occlusive ileus at the Clinic for Surgery, Orthopaedics and Ophthalmology in the period from 1981-1998

Year	N <sup>o</sup> of out-patients	N <sup>o</sup> of in-patients	Total N <sup>o</sup> of dogs	N <sup>o</sup> of dogs with foreign body	% of dogs with foreign bodies in the total N <sup>o</sup> of dogs
1981	805	306	1111	8	0.72
1982	901	299	1200	1	0.08
1983	1012	231	1243	3	0.24
1984	925	238	1163	6	0.52
1985	761	284	1045	7	0.67
1986	828	265	1093	5	0.46
1987	793	117	910	8	0.88
1988	808	253	1061	3	0.28
1989	834	209	1043	5	0.38
1990	977	222	1199	8	0.67
1991	1012	179	1191	3	0.25
1992	1045	125	1170	5	0.43
1993	886	161	1047	6	0.57
1994	972	198	1170	9	0.77
1995	829	186	1015	13	1.28
1996	842	126	968	13	1.34
1997	820	151	971	11	1.11
1998	905	130	1035	9	0.87
Total:	15955	3680	19635	123	0.62

The percentage of incidence of a foreign body found in the small intestine, by individual breeds, is shown in the Table 2.

The results show that mechanically induced ileus in dogs is more frequent in pure-bred dogs (83.74%) than in mongrels. The highest incidence is noted in Dobermann (13%), followed by Poodle (8.13%), German Shepherd and Cocker Spaniel (7.32%).

A large number of patients was received in June (11.38%) and October (11.38%) in contrary to December (3.25%) (Table 3).

Table 2. Incidence of foreign body induced mechanical ileus in pure breed dogs and mongrels

Breed	Number	%
Argentinian Great Dane	1	0.81
Beagle	1	0.81
Belgian Shepherd	1	0.81
Braque	2	1.36
Briar	1	0.81
Dalmatian dog	1	0.81
Dobermann	16	13.0
Epagneul Breton	1	0.81
Erdel terrier	2	1.36
Schnauzer (big / medium)	6 (2/4)	4.88 (1.36/3.25)
Irish Setter	4	3.25
Dachshund	5	4.07
Cocker Spaniel	9	7.32
Labrador	5	4.07
Hunting Terrier	1	0.81
German Great Dane	1	0.81
German Boxer	1	0.81
German Shepherd	9	7.32
German Pointer	5	4.07
German Spitz	1	0.81
Toy-pinch	1	0.81
Pekinese dog	1	0.81
Poodle	10	8.13
Retriever	1	0.81
Rottweiler	7	5.69
Stafford Terrier	3	2.44
Šar-Planina Shepherd	4	3.25
Scottish Terrier	1	0.81
Weimar Pointer	1	0.81
Wolf Spitz	1	0.81
Mongrels	20	16.26
Total	123	

*Clinical examination.* According to data collected from owners, duration of the illness prior to arrival to the Clinic was an average of 6

days. Certain deviations were noted in partial obstructions (8% of cases) where illness persisted between 21 and 60 days before arrival at the Clinic.

Table 3. Number and percentage of dogs with foreign body received at the Clinic by months

Month	Jan.	Feb.	Mar.	Apr.	May	June	July	Aug.	Sept.	Oct.	Nov.	Dec.
No.	11	10	12	10	10	15	6	11	8	14	12	4
%	8.94	8.13	9.75	8.13	8.13	12.19	4.88	8.94	6.50	11.38	9.75	3.25

Table 4. Site and frequency of obstruction caused by a foreign body in certain parts of the digestive tract of dogs with occlusive ileus

Obstruction site	Frequency	%
Oesophagus	2	1.62
Stomach	22	17.88
Duodenum	10	8.13
Jejunum	59	47.97
Ileum	15	12.19
Ileocaecal valve	13	10.57
Caecum	1	0.81
Colon	1	0.81

Findings of the clinical examination showed that more than two-thirds of patients (70%) presented symptoms such as anorexia, dehydration, absence of defecation, depression, vomiting, abnormal appetite and increased tension of the abdominal wall. In most cases, the site of obstruction could be determined by palpation, which caused a painful response from the animal.

*X-Ray examination.* Findings of the X-ray examination in all examined patients confirmed the suspected presence of a foreign body in the digestive tract.

*Treatment.* In the case of a dog that was not subjected to surgery, 3 stones were determined by clinical and X-ray examinations. By *per os* administration of an emetic (copper sulphate), the dog was successfully cured. In addition to receiving conservative treatment, other dogs had to

undergo an operation. Surgical interventions most frequently involved enterotomy (95 dogs), gastrotomy (19 dogs) and intestine resection (12 dogs).

Table 5. Type and incidence of foreign bodies in digestive tract of dogs with occlusive ileus

Foreign body	No. of foreign bodies	Incidence in %
Stone	37	29.13
Rubber balls	16	12.60
Plastic objects	13	10.24
Rubber objects (other)	11	8.66
Horse chestnut	10	7.87
Bones	8	6.30
Stoppers	5	3.94
Marbles	4	3.15
Metal objects	4	3.15
Fibrous objects	4	3.15
Corn cob	3	2.36
Peach kernel	2	1.57
Apricot kernel	2	1.57
Walnut	2	1.57
Glass objects (other)	2	1.57
Salami casing	2	1.57
Paper	2	1.57
Total	127	

Table 6. Survival and fatality rates by age and sex of animal

Age	Sex	Cured	Dead
up to 2 years	males	85.52%	14.48%
	females	83.33%	16.67%
over 2 years	males	79.50%	20.50%
	females	79.16%	20.84%

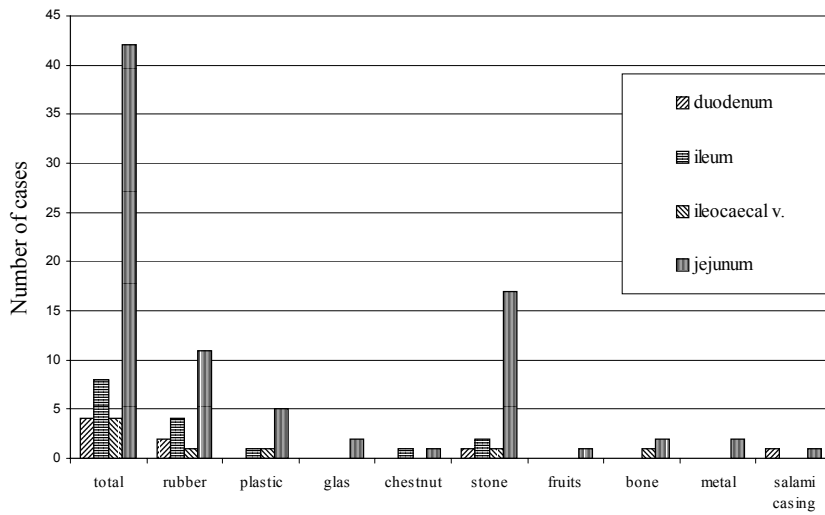


Fig. 1. Sites of obstruction with foreign bodies in dogs which were up to 2 years old

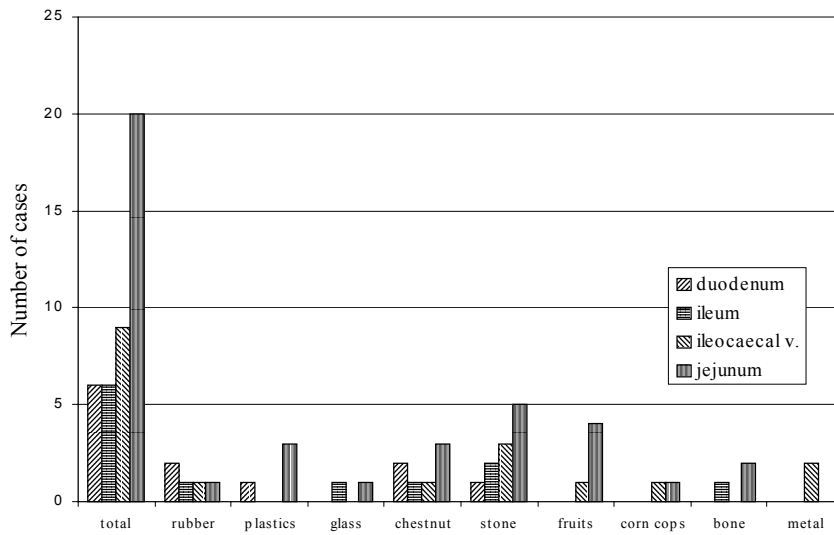


Fig. 2. Obstruction sites and foreign bodies in the patients from 3 to 12 years old



The highest incidence was noted in jejunum (47.97%), and the lowest in caecum and colon (0.81%) (Table 4).

After surgery, the types of foreign bodies were determined. The most frequently ingested foreign bodies were stones (29.13%), whereas walnuts and glass objects were most rarely found (1.57%) (Table 5).

After surgery the animals were kept at the Clinic for an average of 5.81 days and were completely cured within an average of 6.64 days. Regretfully, 17 out of 122 dogs died after surgery: 47.61% (10 dogs) died during the first day after surgery, 19.04% (4 dogs) died the second day after surgery, and 14.28% (3 dogs) died on the third day after surgery. No difference was noted in the number of lethal outcomes between males and females, and with regard to age a slightly larger number of lethal outcomes was recorded among dogs more than 2 years of age (Table 6).

### **Discussion and conclusions**

During an 18-year period, 123 dogs were treated at the Clinic for Surgery, Orthopaedics and Ophthalmology of the Faculty of Veterinary Medicine, University of Zagreb, for mechanical ileus induced by ingestion of foreign bodies. This figure represents 0.62% of the total number of the patients treated at the Clinic during that period .

Data on the share of dogs presenting occlusive ileus caused by ingestion of foreign bodies at our Clinic are similar to those of the Surgical Clinic of the Veterinary Faculty, Hokkaido, Japan, where, over a 15-year period, 0.45% of the total number of treated dogs suffered from ileus caused by ingestion of foreign bodies (KOIKE et al., 1981). The results are also similar to the records of the Surgical Clinic of the Royal Veterinary College in Edinburgh, Great Britain, where occlusive ileus involved 0.49% of the total number of patients (CLARK, 1968).

As far as the sex of animals is concerned, in our research it was found that males ingested foreign bodies more frequently (67%) than females (33%). These findings are similar to those reported by other Clinics.

The large number of male patients in our research may be explained by the fact that people prefer to own male dogs, particularly in case of pure

breeds, where females are mostly kept by breeders and in special holdings, which reduces exposure to potential ingestion of foreign bodies.

Average age of the dogs involved in our research was 3.18 years, where 41.46% of dogs were under the age of 2 years (Fig. 1) and 58.53% were dogs aged from 2 to 12 years (Fig. 2).

These results are similar to those reported by BÖHMER et al. (1990), whose patients were (on average) 3.9 years old. Similar results were also achieved by KOIKE et al. (1981) whose research included 36.22% patients below 12 months of age and 62.06% under the age of 3 years. The reason why the majority of patients were young dogs is that young animals are more vivacious, more curious and less cautious, and the foreign bodies that enter the oral cavity while walking or playing, easily lodge deeper in the digestive tract.

Results of our research also show that ileus caused by ingestion of foreign bodies is more frequent in pure breed dogs (83.74%) than in mongrels. These results are similar to those reported by CLARK (1968), who found that mongrels accounted for 16.26% of patients, and similar to results reported by KOIKE et al. (1981) establishing that mongrels accounted for 6.38%. Such results are most probably due to the greater popularity of pure breed dogs, and also to the fact that mongrels receive less attention.

Among pure breeds this disease most frequently affects Doberman (13%), (Table 2). According to the research carried out by KOIKE et al. (1981), this syndrome was most frequently observed in the Hokkaido-ken breed (38.29%) and less frequently in Dachshund, Scottish Shepherd and Setter (8.51%). In CLARK's researches (1968), the more frequently affected breeds included Labrador (15.78%), Scottish Shepherd (12.63%), German Shepherd and Boxer (7.37%). According to BÖHMER et al. (1990) this disease occurred most frequently in Dachshunds, German Shepherd, Spaniel and Poodle. Differing reports by various authors are most probably due to the varying popularity of certain breeds in different countries. The best example of this are the results achieved by Japanese authors where, due to the extreme popularity of the Hokkaido-ken breed among Japanese dog owners, this particular breed is the most numerous.

With regard to the time of the year, the greatest number of dogs was received at the Clinic in June and October (11.38) and the smallest in

December (3.25%). Such results are probably due to the fact that in wintertime dogs spend less time outdoors and various objects for play (stones, rubber and plastic objects) are covered with snow.

In October, a typical finding was chestnuts, which fall from trees at that time of the year. We found no data on the number of patients classified by seasons or months in the literature and we are therefore unable to compare these results with those of other authors.

Duration of the disease before arrival at the Clinic for examination was an average of 6 days. Certain deviations were noted in partial obstructions, where the disease continued from 21 to 60 days (8% of cases). This makes sense, because the symptoms of partial obstructions are not so severe and therefore are more difficult to notice. An exception was a dog in which the disease continued for about 150 days before arrival for examination. The animal underwent operation and was successfully cured. We presume that this was a case of incomplete ileus, i. e. the foreign body had remained in the stomach first, and then moved into the intestine during the final week of the illness. KOIKE et al. (1981) report that the average period between the onset of symptoms and surgery was 5 days (1-24 days), while BÖHMER et al. (1990) report that most of their patients were received at the clinic within the first four days of onset. The latter results are not in accordance with our own. This may be due to the dog breeding culture, owners' conscientiousness, and the attention they pay to their pets in general.

The main symptoms of ileus caused by ingested foreign bodies noted in 70% of patients were anorexia, vomiting, dehydration, depression, apathy, absence of faecal discharge, abnormal appetite and increased abdominal wall tension. BÖHMER et al. (1990) and KOIKE et al. (1981) mention similar symptoms. In addition to these symptoms, ÜBERREITER (1932) mentioned painful manifestations and back humping, increased heart and respiration rate, elevated temperature, retracted abdomen, unpleasant smell of the animal, while LEHR (1929) also mentioned howling, groaning, colics, and profuse diarrhoea characterized by a small amount of foetid and blood-stained faeces.

The diagnosis was based on anamnesis and clinical examination. The same diagnostic methods were used by other authors (ÜBERREITER, 1932;

CLARK, 1968; KOIKE et al., 1981; BÖHMER et al., 1990). MANCZUR et al. (1998) emphasize in their report the great importance of ultrasonography for rapid diagnosis of intestinal obstruction in dogs.

In 99.2% of the dogs treated at our Clinic, surgery was inevitable and most frequently included enterotomy in 77.23% (95 dogs), followed by gastrotomy in 15.44% (19 dogs) and intestinal resection in 8.94% (11 dogs).

Other authors reported similar results: of 47 dogs - 45 enterotomies and 2 intestinal resections (KOIKE et al., 1981); of 338 dogs - 273 enterotomies, 23 laparotomies, 17 intestinal resections and 5 diagnostic laparotomies (BÖHMER et al., 1990); of 73 dogs - 63 enterotomies, 7 enterotomy-anastomosis combinations, 2 foreign bodies pushed into the colon, and 1 laparotomy (CLARK, 1968); of 348 dogs - 180 enterotomies (others were treated conservatively) (ÜBERREITER, 1932); out of 230 dogs - 125 enterotomies (LEHR, 1929).

The jejunum has been observed to be the most frequent obstruction site (47.97%).

Other authors report similar data: obstruction of jejunum and ileum 31.61%, duodenum 5.17%, ileocaecal valve 1.72% (CLARK, 1968). The reason why foreign bodies most frequently become lodged in the jejunum is connected with its structure. The jejunum is large cranially, gradually narrowing towards the ileum. The foreign body passes through the upper part of the jejunum and then lodges in the medial and caudal part.

The types of foreign bodies are similar to those described in the literature. (Table 6). Other authors also report stones as being the most frequently found foreign bodies: 36.17% KOIKE et al. (1981); 25.45% BÖHMER et al. (1990); 33% CLARK (1968); 72.53% ÜBERREITER (1932) and, in addition to the above mentioned objects, these authors mention nails, needles, coal (CLARK, 1968), textile, fir-cones, wood (BÖHMER et al. 1990), china, sponges, crown corks and various other metal objects (ÜBERREITER, 1932). It is interesting to note that in certain regions (countries) there is a differing variety of foreign objects. In Japan, corncobs rank second (21.27%), immediately after stones, which is typical for the Sapporo region (KOIKE et al. 1981), known for corn growing. The share of these foreign bodies is most probably due to the fact that these objects are the preferred and most frequent dogs' toys.

At our clinic, 83% of patients were completely cured. Such a lower healing rate was due to a longer duration of disease, i. e. relatively late medical intervention. This was because the dogs were brought to the clinic an average of six days after the onset of the disease.

While KOIKE et al. (1982) report on postoperative healing in 93.6% of cases, ÜBERREITER (1932) reports that of 180 dogs treated with enterotomy, 70% were cured, and of 158 conservatively treated dogs 86% were completely cured. According to LEHR (1929) only 50% of dogs to which enterotomy was applied were cured. These data should be duly noted, and may be justified only by the time when they were recorded, i. e. at the time when LEHR (1929) and ÜBERREITER (1932) conducted their research the surgical technique was in its infancy, and the failures may be explained by the unavailability of antibiotics and other necessary drugs.

In conclusion, on the basis of the results achieved through the processing of data collected over an 18-year period at our clinic, we can conclude that the number of dogs with ileus induced by swallowed foreign bodies shows a rising trend in recent years, and that males more frequently ingest foreign bodies than females. Also, it can be noted that ileus induced by ingestion of foreign bodies more frequently occurs in dogs less than 2 years of age, and that mongrels are less prone to ingestion of foreign bodies than pure breed dogs. Among the latter, Dobermann, Poodle, German Shepherd and Cocker Spaniel are more often affected. The most frequently ingested foreign bodies include stones, rubber and plastic objects. The symptoms indicating this syndrome are anorexia, vomiting, absence of faecal discharge, dehydration and increased tension of abdominal wall. The most frequent site of obstruction is the jejunum for which the surgical method of selection is enterotomy. The healing rate is higher in younger animals (up to 2 years of age) and post-operative death most frequently occurs during the first day following surgery. With regard to the incidence of this disease, our research has revealed that this disease showed a slightly rising trend over the past 5 years, indicating that similar research works should be continued.

D. Capak et al.: Treatment of the foreign body induced occlusive ileus in dogs

## References

- BÖHMER, E., U. MATIS, W. ZEDLER, T. HÄNICHEN (1990): Dünndarmileus bei Katze und Hund – katamnestische Betrachtungen von 704 Patienten. *Tierärztl. Prax.* 18, 171-183.
- CAPAK, D., V. BUTKOVIĆ (1991): On the etiology of foreign body induced ileus in dogs. *Vet. arhiv* 61, 297-306.
- CLARK, W. T. (1968): Foreign bodies in the small intestine of the dog. *Vet. Rec.* 83, 115-119.
- CRISTOPH, H. J. (1953): Vergleichende diagnostische und therapeutische Untersuchungen bei Vorkommen von Fremdkörpern im Oesophagus, im Magen und im Darm des Hundes. *Arch. Exper. Vet. Med.* 7, 319-394, 424-503.
- CUNNINGHAM, J. G. (1997): *Textbook of Veterinary Physiology*. 2<sup>nd</sup> ed., W. B. Saunders Comp., Philadelphia, pp. 267-272.
- DIETZ, O., M. GLASER, E. NAGEL, C. SCHNEIDER (1988): Obturation ileus in dog and cat. *Mh. Vet. Med.* 43, 129-132.
- FORENBACHER, S. (1983): *Klinička patologija probave i mijene tvari domaćih životinja*. Vol. I/2 JAZU and Liber, Zagreb.
- GRYGAR, I., R. CHLEBOVSKY (1987): Occlusive ileus in the dog. *Veterinarstvi* 37, 518-519.
- HUNT, G. B., C. R. BELLENGER, G. S. ALLAN, R. MALIK (1991): Suspected cranial migration of two sewing needles from the stomach of a dog. *Vet. Rec.* 128, 329-330.
- KOIKE, T., K. OTOMO, T. KUDO, T. SAKAI (1981): Clinical cases of intestinal obstruction with foreign bodies and intussusception in dogs. *Jpn. J. Vet. Res.* 29, 8-15.
- KYLES, A. E., T. A. SCHNEIDER, A. CLARE (1998): Foreign body intestinal perforation and intra-abdominal abscess formation as a complication of enteroplication in a dog. *Vet. Rec.* 143, 112-113.
- LANTZ, G. C. (1981): The pathophysiology of acute mechanical small bowel obstruction. *Comp. Cont. Ed.* 3, 910-918.
- LAWSON, J. B., M. J. DALLIMORE, I. W. PARRY (1989): Ingestion of sheep sponges by sheepdogs. *Vet. Rec.* 125, 609.
- LEHR, L. T. (1929): *Fremdkörperchirurgie des Magens und des Darmes beim Hunde*. Wien. *Tierärztl. Mschr.* 16, 665-680.
- MANCZUR, F., K. VÖRÖS, T. VRABELY, S. WLADAR, T. NEMETH, B. FENYVES (1998): Sonographic diagnosis of intestinal obstruction in the dog. *Acta Vet. Hungarica* 46, 35-45.
- POBISCH, R. (1960): Die Röntgenuntersuchung des Magen-Darm Traktes beim Vorliegen von Passagehindernissen. Wien. *Tierärztl. Mschr.* 47, 450-465.

D. Capak et al.: Treatment of the foreign body induced occlusive ileus in dogs

SLATTER, D. H. (1993): Textbook of Small Animal Surgery, 2<sup>nd</sup> ed. W. B. Saunders Company, Philadelphia, pp. 593-612.

ÜBERREITER, O. (1932): Die Indikation zum operativen Eingriffe beim Fremdkörper in Magen und Darne des Hundes. Wien. Tierärztl. Mschr. 19, 449-459, 481-491.

WILLIAMS, J. R. L. (1989): Ingestion of sheep sponges by sheepdogs. Vet. Rec. 125, 658.

Received: 20 September 2001

Accepted: 20 December 2001

---

**CAPAK, D., A. BRKIĆ, I. HARAPIN, D. MATIČIĆ, B. RADIŠIĆ: Liječenje ileusa izazvanog stranim tijelom u probavnoj cijevi pasa. Vet. arhiv 71, 345-359, 2001.**

**SAŽETAK**

Istraživana su 123 pacijenta koji su liječeni od stranih tijela u probavnom sustavu od 1981. do 1998. godine na Klinici za kirurgiju, ortopediju i oftalmologiju Veterinarskog fakulteta Sveučilišta u Zagrebu. Prikazana je učestalost ileusa uzrokovanog stranim tijelima s obzirom na spol, dob, pasminu, trajanje bolesti, mjesto opstrukcije i vrstu stranog predmeta. Rezultati istraživanja pokazuju da se povećava broj pacijenata s ileusom uzrokovanim stranim tijelom. Mužjaci češće progutaju strano tijelo nego ženke. Ileus uzrokovan stranim tijelom češći je u pasa mlađih od dvije godine. Strano tijelo češće progutaju križanci, ali i čistokrvni psi, kao na primjer doberman, pudli, njemački ovčari i koker-španijeli. Većina pacijenata liječena je u lipnju i listopadu. Dominantni klinički znakovi su bili anoreksija, dehidracija, bol u trbuhu i nedostatak velike nužde. Najučestalije mjesto zastoja stranog tijela je tašto crijevo, a najbolja je terapija enterotomija. Psi najčešće progutaju kamenje, plastične i gumene predmete. Liječenje je najuspješnije u pasa mlađih od dvije godine. Pacijenti koji nisu preživjeli nakon operacijskog zahvata, uginuli su najčešće prvog dana nakon operacije.

**Ključne riječi:** strana tijela, ileus, probavni trakt, pas

---